

Comparison of Acoustic Properties of Voice Quality Before and After Thyroplasty Medialization

Varošanec-Škarić, Gordana; Stevanović, Siniša; Bašić, Iva

Source / Izvornik: **Applied research in human and social sciences, 2019, 57 - 72**

Book chapter / Poglavlje u knjizi

Publication status / Verzija rada: **Published version / Objavljena verzija rada (izdavačev PDF)**

Permanent link / Trajna poveznica: <https://um.nsk.hr/um:nbn:hr:131:831869>

Rights / Prava: [In copyright](#)/[Zaštićeno autorskim pravom.](#)

Download date / Datum preuzimanja: **2024-07-11**



Sveučilište u Zagrebu
Filozofski fakultet
University of Zagreb
Faculty of Humanities
and Social Sciences

Repository / Repozitorij:

[ODRAZ - open repository of the University of Zagreb
Faculty of Humanities and Social Sciences](#)



Comparison of Acoustic Properties of Voice Quality Before and After Thyroplasty Medialization

Gordana Varošanec-Škarić¹, Siniša Stevanović²

¹University of Zagreb, Department of Phonetics
Ivana Lučića 3, 10 000 Zagreb, Croatia

²University Hospital Centre “Sisters of Charity”
gvarosan@ffzg.hr, stevanovic.sin@gmail.com

Iva Bašić¹

ibasic@ffzg.hr

ABSTRACT

After vagus nerve was recessed, due to the resulting gap and lack of adduction voice quality was poor, the timbre was completely unharmonic and phonation type whispery. Six years after the surgery thyroplasty type I (medialization thyroplasty) was conducted. Before and after the procedure the following data were collected: subjective assessment of voice quality, (VHI), phonetic, auditory assessment, and acoustic analysis including: F0 measures, tone and intensity perturbations, HNR during phonation, and long term average spectrum (LTASS). After thyroplasty the subjective assessment was that there is no voice quality disorder. Phonetic protocols provided information about complete comprehensibility, good speech quality, optimal communication, middle tone, normal loudness, no supralaryngeal modifications, modal phonation, adequate breathing and rhythmicity. Acoustic parameters indicated significant differences in jitter ($p > 0.0001$), shimmer ($p = 0.001$), dispersion F0 ($p = 0.002$) and HNR ($p = 0.005$). Regarding timbre, during reading and spontaneous productions showed more balanced LTASS. Interdisciplinary approach motivates patient because higher voice quality improves life quality.

Key words: voice quality, medialization thyroplasty, VHI questionnaire, phonetic assessment, acoustic analysis

1 INTRODUCTION

The impact of voice quality on individual's life quality is well known. Both functional and social aspects of life quality are addressed. Usually, poor voice quality is related to general health and the removal of tumor tissue does not necessarily mean the postoperative improvement of voice quality. Unfortunately, it

can even worsen due to the nature of the syndrome, even with voice therapy. The causes are complicated, and in this paper voice quality of a patient after tumor removal will be described according to phonetic protocol. Benign tumor was removed from vagus nerve after which voice quality was very poor. Before the primary operation the patient suffered pain in lower neck area up to the right ear, but no problems with swallowing or breathing were detected. Vocal cords were motorically functional i.e. active during breathing and phonation. Considering the fact that vagus nerve was recessed, right vocal cord was laterally moved and fixed. Therefore, during phonation no adduction occurred and a noticeable gap 4 – 5 mm remained (Figure 1 – pre vocal cord surgery). Voice quality was poor, the timbre was completely inharmonic and phonation completely whispery. Six years after reporting described voice difficulties and dysfunctionality, the patient (aged 69) was surgically treated (thyroplasty type I, i.e. medialization of the right vocal fold to compensate the 1 mm gap due to the incapacity to move. Unlike the preoperative state, it is evident that the vocal cords are in the state of complete adduction during phonation (Figure 1 – post vocal cord surgery).

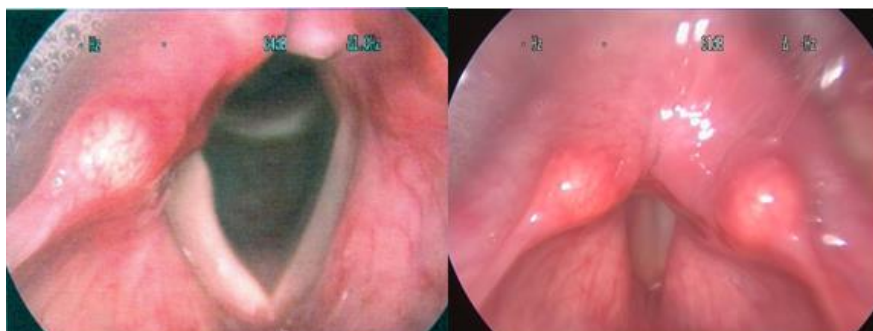


Figure 1: Vocal cords before (left) and after (right) the surgical procedure (thyroplasty type I)

Medialization thyroplasty is used for unilateral vocal fold paralyses (UVFP) as a reliable treatment of hoarseness cancer-related group and the benign group (Lam et al. 2007). It is interesting that the technique of thyroplasty type I was described some 100 years ago – in 1915 and it was rediscovered and returned as a phonosurgical technique when it was described by Isshiki et al. 1974 (Ng et al. 2008, Ryu et al. 2012). In the last decades, it proved to be a reliable treatment for UVFP patients.

The subjective assessment of the patient's voice, phonetic protocol and acoustic analysis before and after the surgery (thyroplasty type I: medialization thyroplasty) were compared. The non-functional voice was a result of the primary operation (dated six years before) and was compared to voice quality two weeks after thyroplasty.

VHI (Voice Handicap Index) questionnaire developed by Jacobson et al. (1997) and adapted to Croatian by Tomić and Varošanec-Škarić (2015) was used

for subjective assessment. The index determines life quality related to voice quality. Since the dysphonia was caused by various causes, patients' life quality is negatively affected (i.e. Hidayat et al. 2018), the social, professional and emotional life, therefore the purpose of this case study is to examine how the self-assessment of the patient's life quality changes in the aforementioned domains before and after the procedure.

Regarding the other psychometric scales, such as Vocal Performance Questionnaire, a short version of VHI can be used, containing only 10 items (VHI-10) (Deary et al., 2004). Validation of the entire questionnaire (30 items) was completed for numerous languages (Dutch, Flemish (Belgium), English (UK); French, German, Italian, Portuguese and Swedish to confirm the validity of the original and the European translations (Verdonck-de Leeuw et al., 2008). The purpose of the validation for each particular language is to compare results from different countries. What Guimarães and Abberton (2004) did was a preliminary adaptation of VHI on Portuguese speakers. VHI comprises of three subscales: functional (F), physical (P) and emotional (E). Numerous studies have confirmed the validity of VHI in discrimination of healthy and dysphonic voice qualities. Furthermore, expert assessment included swallowing assessment, postoperative life quality, SLP treatment and description of voice quality based on descriptive phonetic protocol and clinical VPA protocol (regularly used in voice quality studies, clinical context and differentiation of pathological, normal and aesthetically pleasant voice qualities (Varošaneć-Škarić, 2008; 2010). The analysis compared to measuring points - before and after the surgical procedure. Acoustic measures informing about timber can, on one hand, argue about the success of the surgical procedure objectively and on the other support the patients' self-assessment and expert assessment of the voice quality. For an example, after thyroplasty acoustic and perceptual data can be correlated (Plant et al. 1997), acoustic changes in patient's voice after medialization thyroplasty can be examined (Ng et al., 2008), or the long-term voice outcomes based on phonation can be measured (Ryu et al. 2012). Following that study, the acoustic analysis in this study included the following parameters which combined provide a complete description of voice quality: F0 measures (Hz), frequency and amplitude perturbations (local jitter and shimmer), HNR (dB), comparison of long term average spectrum in speech (LTASS) and vowel phonation time.

2 METHODS

2.1 Surgical technique employed

Both surgical procedures were done in the University Hospital Centre "Sisters of Charity"- Otorhinolaryngology, Head and Neck Surgery in Zagreb. The first procedure was done in April 2011 and the second in February 2018. It was said that the first procedure was done because of the vagus nerve tumor, particularly nervus laryngeus superior branch, responsible for the laryngeal and

pharyngeal sensation and nervus laryngeus inferior (recurrent laryngeal nerve). Since the recurrent laryngeal nerve activates laryngeal muscles and enables vocal folds' motor activation, it is expected that the right vocal fold was laterally displaced, therefore the adduction of the vocal folds did not occur leaving the 4-5 mm gap between them. During the first procedure vagus nerve was recessed. Following the procedure, the patient (female, native speaker of Croatian) was suffering from aphonia, the voice was aspirated – strongly whispery i.e. with quite poor voice quality. This resulted in patient's low assessment of her life quality and those functional reasons and the desire for better communication, the second procedure was necessary. In this case, the second procedure was tyroplasty type 1, i.e. medialization tyroplasty enabling the movement of the vocal fold medially. The technique included horizontal neck F1 long, platysma was removed and infrahyoid muscles approached. They were partly moved and partly recessed. The thyroid cartilage of the larynx was approached, the perichondrium was removed, and a drill hole was made in the lower part of the thyroid cartilage, the internal perichondrium was carefully lifted, and medialization of the vocal fold was done by placing the Gore-Tex band through the opening. The Gore-Tex implant was about 0.4 mm thick, about 3-5 mm wide, and the amount of tape (implant) required for medialization was assessed by the auditory assessment of the patient's voice. The more tape was put on, the better the voice quality was. In order not to put too much Gore-Tex implant and not to jeopardize the patient's breathing, a fiberoendoscopic control was performed with a camera that runs through the nose to the vocal folds and allows visual control of the vocal folds position. After this procedure, the complete adduction of vocal cords in phonation was achieved, unlike after the first procedure.

2.2 Voice recording and voice assessment

The first recording session was done at the end of 2017, two months before the second procedure, i.e. medialization tyroplasty and the second recording was conducted in 2018, two weeks after the surgical procedure (thyroplasty type I) in the silent room at the Department of Phonetics – University of Zagreb. Since the time required from the procedure to the postoperative recording is not standardized (Ryu et al. 2012), the common practice is to record the patients two weeks after the surgery, because in the similar previous cases the time is sufficient for the voice stabilization so that the recordings can be perceptually and acoustically assessed. Moreover, if the patients' general condition is good and there are no postoperative difficulties. The postoperative time variable will be further explained in the Comments section. Tests for the assessment of voice quality were recorded following phonetic protocol (cca 2 x 70 s), as well as spontaneous productions in an interview with a phonetician and finally five repeated phonation samples for each of Croatian vowels [a, e, i, o, u]. The entire recording process, from the interview to the phonation monitoring was controlled by two phoneticians and an expert associate who was in the second room monitoring the technical conditions

and digital recording. Condenser microphone was placed at 10 cm distance from the patient's mouth. Sampling rate was 44 100 Hz.

2.3 Self-assessment and auditory assessment with phonetic protocol

After each recording session the patient completed VHI questionnaire. Phonetician used phonetic clinical voice quality protocol used for assessment of various voice disorders, for the assessment of voice quality before and after surgery. The comparison of VHI indices serve as a motivation for the patient but are quite informative for the expert to follow longitudinal changes of voice. According to the VHI questionnaire (Jacobson et al., 1997) 30 items are subjectively assessed examining the degree of impairment on a three subscales (F, P and E) with 10 statements for each. Five-degree Likert scale is used for the assessment of the statements (0 to 4): 0 – never (0 point), 1 rarely (1 point), 2 – sometimes (2 points), 3 – often (3 points), 4 – always (4 points). The questions are randomized, there is no information about scoring and the answers indicate personal assessment. In the questionnaire the statements are followed by assessment of the concern about voice, assessment of the current state (without problems, with mild problems, with moderate problems or with severe problems), and two statements about talkativeness and loudness (assessed on a 1 to 10 scale).

The expert assessment of patient's voice quality was conducted before and after thyroplasty in functional factors of social voice quality measured by comprehensibility, overall voice quality, speech rate and ability to communicate. There are five degrees of assessment of tone and loudness in phonetic protocol, three degrees of assessment of supralaryngeal modifications (mild, moderate and severe) and finally phonation type. More complex clinical protocol for vocal profile analysis (VPA; Laver et al., 1981; adapted by Varošanec-Škarić, 2010) includes six degrees of assessment (typical and atypical) of voice quality – A) supralaryngeal setting, B) laryngeal setting; in three degrees of prosodic features (pitch, consistency – e.g. tremor and loudness) and temporal organization features (speech continuity, rate and other (breath support, rhythmicity and diplophonia).

2.4 Acoustic parameters and procedures

Before and after right vocal fold medialization thyroplasty the following average values from the mid sections of vowel phonations from five repeated samples for each vowel were collected: average F0, F0 standard deviation, F0 minimum and maximum (in Hz), F0 perturbation measures (local jitter u %) and amplitude (local shimmer dB), ratio of harmonic and noise elements (HNR u dB). Acoustic analysis was conducted in Praat program (Boersma & Weenik, 2015), version 6.0.31. For the illustration but also the control of expert auditory assessment narrow spectrograms and oscilograms of the phonation samples were made. Phonation time (Tf) was based on the duration of the entire vowel

phonation. The comparison of timbre was done by long term average spectrum (LTASS) procedure from reading (cca 70 s sample duration) and spontaneous production of similar duration collected in a longer conversation with a phonetician.

The results of the acoustic measures were analyzed in SPSS statistical package. The descriptive statistic was calculated for the acoustic parameters' results before and after thyroplasty, and t-test was used for comparison of the vowel phonation results before and after the procedure.

3 THE RESULTS

3.1 Comparison of VHI results and expert assessment

According to the overall results of the self-assessment pre-surgery results show moderate degree of voice handicap (45 compared to the reference point of 44.37) while after the procedure the patient feels that there is no handicap (post-surgery score is 23). Mild handicap is scored 33.69 on the entire item set. When analyzing sub-scales, the greatest improvement is noted on functional and physical scales while the least improvement is seen on the emotional scale. Before the procedure, the patient's score was 24 on the physical sub-scale (the reference point is 22.78) meaning that the patient felt severe handicap. The handicap on the functional sub-scale was mild (16 points in comparison to 12.41), while no handicap was perceived on the emotional sub-scale scoring only 5, while the reference point is 8.08 (*Table 1*).

Table 1: Comparison of VHI results before and after thyroplasty procedure

Scale	Before	After
Functional (F)	16 (SD=1,75)	5 (SD=0,68)
Physical (P)	24 (SD=1,28)	14 (SD=0,8)
Emotional (E)	5 (SD=0,65)	4 (SD=0,64)
Total	45 (SD=1,52)	23 (SD=0,84)

The result from the emotional sub-scale can be explained with the fact that the patient was retired when data was collected, so no business contacts were included in her routine during which she was forced to use her voice more or communicate in larger groups which could then affect her emotional state due to higher stress level, social life, shame, inability caused by lower voice quality. Subjective perception of severe handicap measured by the physical scale (P) before the surgery referred retrospectively to constant hoarseness, great speaking

effort, tension in voice production, lack of breath in speech, change in voice quality during the day, and questions about voice problems. Self-perception of the mild damage on the functional subscale (F) referred to (scored always) difficulties with being heard in conversation, not being understandable in loud rooms or at home when talking to family, requests for repetition and that sometimes patient's personal and social life are limited by her voice problems. Before the procedure the patient said that worry about voice problems was moderate as well as voice state, talkativeness and loudness (5 on a 1 to 10 scale). This shows that the self-assessment is milder than the physical problems and compared to the expert assessment of functional factors of social life quality. After the procedure the self-assessment of worry about voice problems and voice state show milder problems, talkativeness is greater as well as loudness.

3.1.2 The results of comparison according to phonetic protocols

Functional factors of social life quality show that the voice before the thyroplasty was not intelligible, overall speech quality is low, tempo is rated as acceptable, but not fluent enough, and communicative ability as poor. Two weeks after the surgery the voice was completely intelligible, good overall voice quality, acceptable and appropriate speech rate, optimal communication ability. According to phonetic protocol tone could not be assessed before the surgery due to non-harmonicity (Figure 2 and 3 left), voice was very quiet, supralaryngeal and laryngeal settings were lax, phonation type was severe whisper (level six) and whispery (level six), the tremor level was not usual (level two), smoothness i.e. continuity was inappropriate (level two), speech rate was inappropriate (level one), as well as breathing (level three), rhythmicity (level tow). Two weeks after the surgery the loudness was medium, without noticeable supralaryngeal and laryngeal modifications, sufficient harmonicity as one would expect in a normal voice, phonation type modal, which is a feature of a normal voice (Figure 3 right), and sporadically during phonation of an open vowel [a] harsh voice as a subtype of modal phonation is present as a subtype of modal phonation (Figure 2 right). After thyroplasty, reading sample and spontaneous production sample show dominance of the normal voice. Tone level is within normal female range, tension is neutral, continuity and speech rate are appropriate, as well as breathing and rhythmicity. Therefore, the self-assessment results and the experts' assessment show that voice quality and speech intelligibility improved after the procedure. Postoperative speech functionality indicated that the patients can produce fluent and intelligible speech in native language (Lam et al. 2007).

3.2 Acoustic analysis

F0 values were calculated from the phonation before the surgical procedure and cannot be uncritically considered correct, because of the non-harmonic sound. This indicates other glottal phenomena. The non-harmonic sound is seen on the

narrow spectrograms (Figure 2 and 3 left), and confirmed by the average ratio of harmonic and noise elements (HNR in dB) which is for all vowels very low and indicate disordered voice. The values range from 0.54 dB (vowel [u]) to 6.17 dB (vowel [i]), being extremely low compared to minimum reference point which for normal voice is 20 dB, and which confirms dominance of noise component. The instability of F0 calculation is evident from high dispersion F0 (S.D._F0) ranging from 13.11 Hz (vowel [a]) to even 23.57 Hz (vowel [i]). After thyroplasty the adduction was possible therefore harmonic sound was produced. HNR values are greater for all vowels, and completely normal values (20 dB and higher) were measured for vowels [i], [o] and [u] (Table 2), average value is 21.71 dB which falls in the range of normal voice. F0 could be calculated correctly (confirmed by harmonic sound on narrow spectrograms – Figure 2 and 3 right), and in the phonation ranges from 143.12 Hz (vowel [a]) to 201.37 Hz (vowel [i]) which is expected for normal female voice. Also, dispersions are significantly lower (S.D._F0), tone is more stable. Phonetic description of phonation types before and after procedure was confirmed by oscilograms (calculated from short phonation samples in order to detect the wave form on time and amplitude axes) showing dominance of the whisper phonation type before the procedure and which is evident in irregularities and weak amplitudes (Figure 2 and 3 left) and modal phonation especially in back vowels (Figure 3 right). Although vowel [a] partly shows modal phonation with F0 drop, so it is described as harsh voice (subtype of modal phonation). Tone aperiodicity measures (local jitter in %) was highly pathological for all vowels before the procedure ranging between 6.23 % for [a] and 8.26 % for [u], with average values of even 7.12 %. After thyroplasty the average jitter value of 0.89 % is within normal range considering the reference point of pathological aperiodicity of F0 during phonation is 1.1 % measured by Praat program. Only the most open vowel [a] did not fall within normal values (2.68%), while the front tense and back vowels do. Amplitude aperiodicity measures (local shimmer in dB) was pathological before the surgery for all vowels and the average values was 1.78 dB, while after the procedure the average values were 0.35 which is a border value due to the instability of the vowel [a]. It is difficult to achieve complete adduction for open vowel due to the lack of tension. All other vowels show average local shimmer values within range for normal voice (i.e. below 0.35 dB).

Table 2: Comparison of averages for acoustic measures before (B) and after (A) medialization thyroplasty

		F ₀ (Hz)	S.D._F ₀	min F ₀	max F ₀	Jitter (%)	Shimmer (dB)	HNR (dB)	Tf
[a]	B	271,98	13,11	231,05	296,53	6,230	1,84	2,04	2,32
	A	143,12	4,57	134,07	158,66	2,687	0,97	9,13	4,18

[e]	B	192,27	15,41	164,68	217,62	7,310	1,76	5,87	1,73
	A	151,36	5,12	137,76	160,58	0,647	0,26	18,63	5,89
[i]	B	186,14	23,57	143,21	230,52	6,620	1,72	6,17	1,87
	A	201,37	3,30	194,43	209,60	0,374	0,12	26,14	5,70
[o]	B	145,96	14,28	118,06	168,68	6,970	1,74	2,11	2,00
	A	188,93	3,33	180,75	194,98	0,383	0,24	25,42	5,70
[u]	B	181,73	19,89	146,58	216,90	8,260	1,83	0,54	1,58
	A	200,03	6,86	186,44	212,69	0,335	0,20	29,25	4,69
Total	B	193,23	17,17	158,83	223,37	7,12	1,78	3,39	1,89
	A	176,96	4,64	166,69	187,30	0,89	0,35	21,71	5,23

Table 3: The t-test results for acoustic parameters (vowel phonation samples) before and after medialization thyroplasty

	F ₀ (Hz)	S.D._F ₀	min F ₀	max F ₀	Jitter (%)	Shimmer (dB)	HNR (dB)	Tf
[a]	0,04587	0,01997	0,081	0,039274	0,0644269	0,0036702	0,0135437	0,0257285
[e]	0,59899	0,00734	0,7282	0,471789	0,0004793	0,0000005	0,0000002	0,0284142
[i]	0,63615	0,01399	0,088	0,614168	0,0005038	0,0000067	0,0000006	0,0363618
[o]	0,09892	0,0045	0,0121	0,2989	0,0000163	0,0000683	0,0004393	0,0332882
[u]	0,46759	0,039	0,1154	0,875282	0,0001975	0,0000035	0,0000020	0,0039521
	F ₀	SD	min F ₀	max F ₀	Jitter	Shimmer	HNR	Tf
Total (p)	0,467	0,002	0,049	0,149	0,00001	0,001	0,005	0,0002

The overall results of the acoustic analysis based on the vowel phonation before and after thyroplasty show the greatest significance (t-test) for local jitter

measures ($p < 0.0001$), phonation time ($p < 0.001$), followed by shimmer ($p = 0.001$), F0 dispersion ($S.D._{F0} = 0.002$) and HNR ($p = 0.005$) (Table 3). Phonation time as a temporal acoustic measure is significantly longer after the surgery, but is still far from the desirable 25 s, which can be explained by the short post-surgery period of two weeks. The patient is included in the speech therapy so it can be expected that the phonation time will increase. The results of the acoustic analysis support auditory assessment and confirm the improvement of voice quality after the surgery, i.e. fundamental frequency was more stable, firm and harmonic.

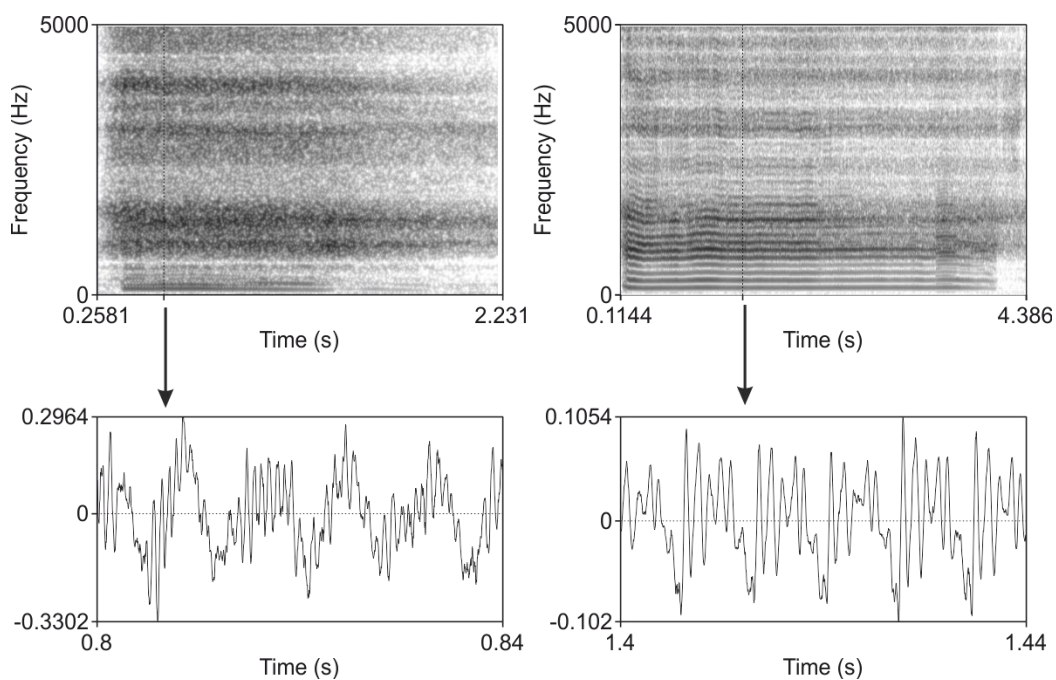


Figure 2: Narrow spectrogram (upper images) and oscillograms (lower images) of vowel [a] phonation before (left) and after (right) thyroplasty medialization

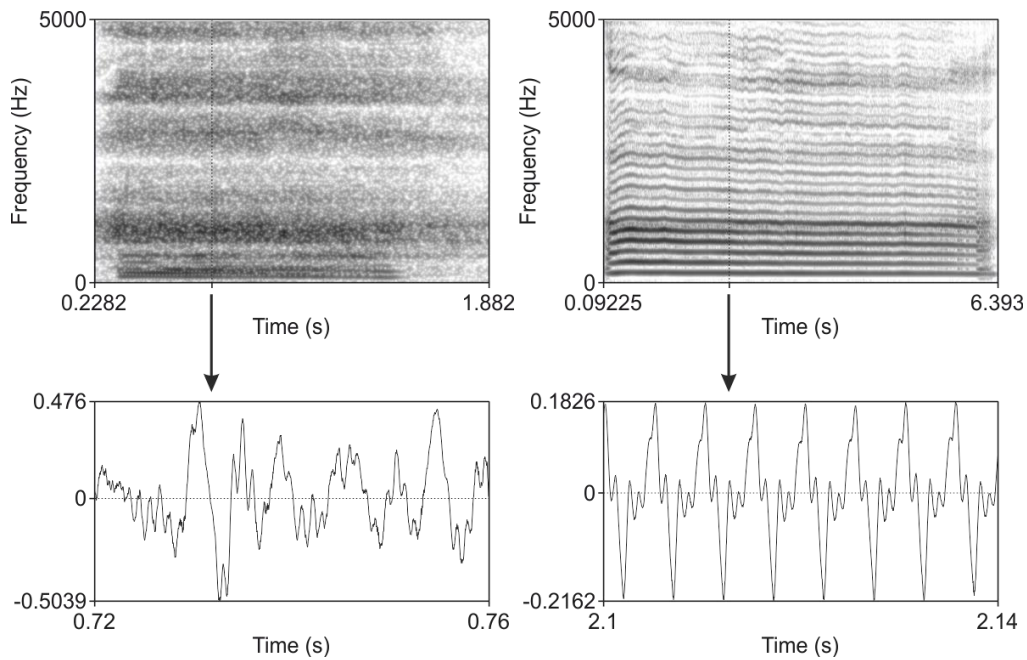


Figure 3: Narrow spectrogram (upper images) and oscillograms (lower images) of vowel [o] phonation before (left) and after (right) thyroplasty medialization

Long term average spectrum of speech (LTASS)

Long term average spectrum of speech (LTASS) was analysed from reading samples and spontaneous production samples (70 s each) in Praat program. The LTASS analysis provides information about timbre before and after the thyroplasty type I. It is evident that the spectrum (in the area between 0.07 and 10 kHz) is significantly more balanced after the procedure (thicker line) since the adduction of vocal cords is achieved in both conditions – controlled reading of the Voice text test (Figure 4) and during interview with the phonetician (Figure 5). Before the surgery F0 was weak and not dissociated, moving within extremely low values of severely whisper and whispery voice, ranging from 117 Hz (in reading) to 131 Hz in spontaneous speech. After the procedure F0 is more dissociated, average values are falling within the scope of female voice ranging from 160 Hz (in reading) to 176 Hz in spontaneous speech. The spectral balance is evident in mild falling of F0 till the end of spectrum, while before the procedure it was unbalanced i.e. non-harmonic spectrum was evident in greater antiformant antiresonant elements in voluminosity and brilliance. Due to the imbalance, higher spectral areas are stronger than lower, which are features of pathological voices: roundness is stronger than sonority, being the reversed timbre of unpleasant voices. While after the procedure roundness is balanced with lower spectral areas,

antiresonant areas are very narrow on the frequency scale. Also, voluminosity is adequate for normal female voice and the fullness area is significantly stronger which is the sign that loudness is normal.

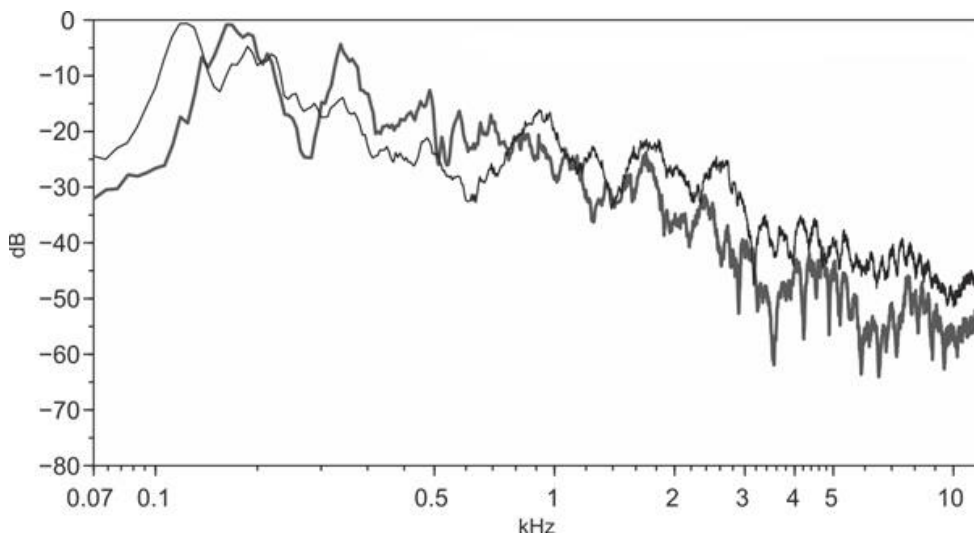


Figure 4: Long term average spectrum of speech (LTASS) of patient in reading samples before thyroplasty medialization (thinner line) and after (thicker line)

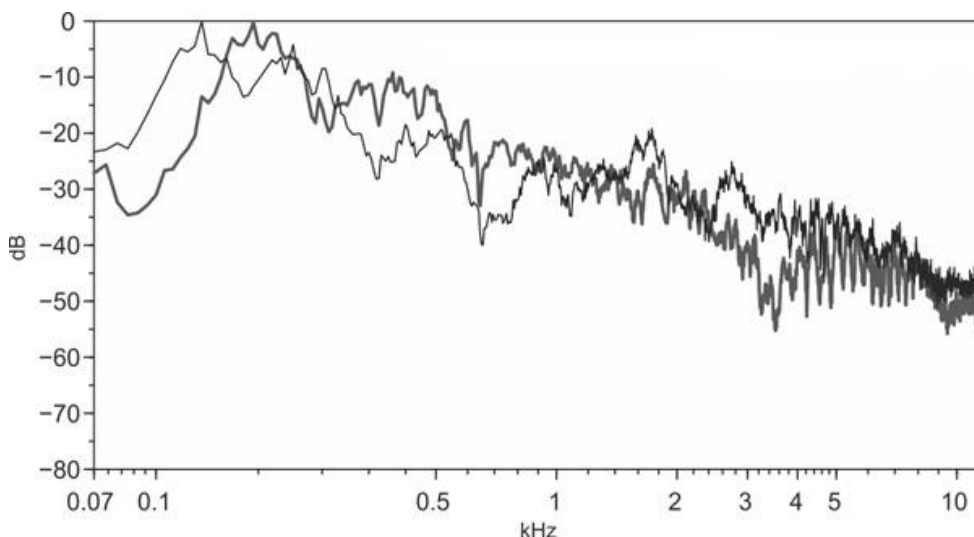


Figure 5: Long term average spectrum of speech (LTASS) of patient in spontaneous production samples before thyroplasty medialization (thinner line) and after (thicker line)

4 COMMENTS

The approach in this case study was to compare the voice quality before and after the second surgical procedure. The second procedure was medialization thyroplasty technique while the voice quality assessment techniques resulted from the desire for interdisciplinary research connecting surgeons specialized in phoniatrics and phoneticians focusing more on the voice aesthetics and timbral acoustic properties. Although it is common that voice quality is assessed by speech pathologists, in Croatian practice phoneticians are also included. Phonetic protocol for voice quality assessment include laryngeal and supralaryngeal categories because voice quality should be assessed by both perceptive and acoustic assessment. Therefore, the assessment did not only include the phonation of vowel [a], but also all other cardinal vowels because long term average spectrum is influenced by all vowels and timbre. Voice quality is assessed on the basis of speech, since speech provides other information, in addition to timbral features, such as prosodic and other speech characteristics (temporal, elegance, etc.) Therefore, it is logical to include in the voice assessment the long-term average speech spectrum (LTASS) based on speech duration of about 70 s, because for the auditory assessment the voice quality in the continuous speech is also important. It is important for the patient's self-assessment, for his/her listeners, surgeons and phoneticians assessing voice quality and timbre as a perceptive manifestation of voice quality. Therefore, the interdisciplinary approach was encouraged by using VHI questionnaire regularly used by speech pathologists which was verified for clinical purposes in Croatia by, as mentioned before, phoneticians.

In this case-study the patient was recorded two months before and two weeks after the procedure. Considering the circumstances, the patient recovered from the procedure very fast, followed the instructions on postoperative voice sparing and was really satisfied with her voice and communication after the procedure, we wanted to examine whether the voice can stabilize in such a short period. In the case of longitudinal studies of the vocal quality of a group of patients, e.g. with the aetiology of unilateral vocal cord pulsy (UVCP), the longitudinal postoperative voice is recorded and evaluated between one and three months, then after six months, one year and possibly after five years (see Ryu et al. 2012). In any case, a number of reasons may affect the timing of postoperative recording of the patient's voice, for example, it may depend on preoperative aetiology, the choice of objective measures, research objectives. For example, for acoustical voice analysis before and after thyroplasty, the voice can be recorded postoperatively after two weeks, and if aerodynamic voice analysis is considered after the same procedure, then it is reasonable for six months after the measurement and comparison procedure. In any case, the post-operative six months is sufficient time to completely stabilize voice quality. Our opinion is that five years after surgery for benign diseases voice should not be re-recorded unless the patient seeks expert opinion for a particular reason. After that period, there is no point in comparing vocal quality as age-related changes occur. It should also be

borne in mind that patients between the ages of 50 and 70 have the procedures more often than very young patients. Of course, elderly patients with malignant aetiology may be postoperatively assessed after shorter period of time because of the life expectancy. Medialization thyroplasty for patients with cancer-related UVFP has been shown to be as safe and effective phonosurgical technique as well as for patients with benign aetiology (Lam et al., 2007). Therefore, medialization thyroplasty technique is nowadays prevalent in the cases of UVFP, as all patients have improved voice quality after the procedure and better social communication and better life quality.

5 CONCLUSION

This paper examines the relation between self-assessment and expert assessment of voice quality before and after surgical procedure (thyroplasty type I) compared to acoustic analysis of voice quality. VHI was a useful tool for comparison of pre and post-surgery self-assessment. It is evident that the better voice quality showed better results on Functional and Physical subscales. The expert assessment following phonetic protocol confirmed the improvement of voice quality and the change of phonation type from pathological whisper to mostly modal voice quality. Finally, acoustic parameters have shown that after medialization thyroplasty voice quality improvement is evident from better periodicity of fundamental frequency and amplitude perturbation, stable F0 and significantly better ratio of harmonic and noise elements in spectrum. The overall impression of patient's timbre after the surgery is that the LTASS showed balanced envelope of a normal female voice.

Equally important, the goal was also the motivation towards patient, since good voice quality significantly influences patient's satisfaction.

REFERENCES

- Boersma, P., & Weenik, D. (2015). Praat: doing phonetics by computer, <http://www.fon.hum.uva.nl/praat/> (July 27, 2018).
- Deary, I. J., Webb, A., Mackenzie, K., Wilson, J. A., & Carding, P. N. (2004). Short, self-report voice symptom scales: Psychometric characteristics of the Voice Handicap Index-10 and the Vocal Performance Questionnaire. *Otolaryngology-Head and Neck Surgery*, 131, 3, 232-235.
- Guimarães, I., & Abberton, E. (2004). An Investigation of the Voice Handicap Index with Speakers of Portuguese: Preliminary Data. *Journal of Voice*, 18 (1): 71-82.
- Hidayat, R. C., Saragih, A. R., Zahara, D., Adenin, L. I., Zalachu, F. (2018). Dysphonia Causative Diagnosis Linked to Voice Handicap Index of the

Patients with Dysphonia. *International Journal of Scientific Study*, 6 (1): 134-137. (DOI: 10.17354/ijss/2018/126).

Isshiki, N., Morita, H., Okamura, H., Hiramoto, M. (1974). Thyroplasty as a new phonosurgical technique. *Acta Otolaryngol.*, 78 (5-6): 451-457.

Jacobson, B. H., Johnson, A., Grywalski, C., Jacobson, G., & Benninger, M. (1997). The Voice Handicap Index (VHI): Development and Validation. *American Journal of Speech-Language Pathology*, 6, 3, 66-70.

Lam, P. K. Y., Ho, W. K., Ng, M. L., Wei, W. I. (2007). Medialization thyroplasty for cancer-related unilateral vocal fold paralysis. *Otolaryngology-Head and Neck Surgery*, 136, 440-444. (doi: 10.1016/j.otohns.2006.11.009)

Laver, J., Wirz, S., Mackenzie, J., Hiller, S. (1981). A perceptual protocol for the analysis of vocal profiles. *Edinburgh University Department of Linguistics Work in Progress*, 14, 139-155.

Ng, M. L., Wong, R. K., Wei, W. I., Lam P. K. Y. (2008). Acoustic Changes in Chinese Patients With Cancer-Related Unilateral Vocal Fold Paralysis After Medialization Thyroplasty. *Contemporary Issues in Communication Science and Disorders*, 35, 17-24, 109-5171/08/3501-0017.

Plant, R. L., Hillel, A. D., Waugh, P. F. (1997). Analysis of Voice Changes After Thyroplasty Using Linear Predictive Coding. *Laryngoscope*, 107, 703-709.

Ryu, I. S., Nam, S. Y., Han, M. W., Choi, S-H. (2012). Long-term Voice Outcomes After Thyroplasty for Unilateral Vocal Fold Paralysis. *Arch Otolaryngology Head and Neck Surgery*, 138, 4, 347-351 (<https://jamanetwork.com/on> 06/18/2019)

Stránik, A., Čmejla, R., Vokřál, J. (2014). Acoustic Parameters for Classification of Breathiness in Continuous Speech According to the GRBAS Scale. *Journal of Voice*, 28, 5, 653.e9-653.e17.

Tomić, D., & Varošanec-Škarić, G. (2015). Validation of Croatian voice handicap index. In M. Sovilj, & M. Subotić (Eds.). *Speech and Language 2015*. Beograd: Draslar Partner.

Varošanec-Škarić, G. (2008). Acoustic characteristics of voice and vocal care in acting and other students. *Clinical Linguistics and Phonetics*, 22, 881-889.

Varošanec-Škarić, G. (2010). *Fonetska njega glasa i izgovora*. Zagreb: FF press.

Verdonck-de Leeuw, I. M., Kuik, D. J., De Bodt, M., Guimaraes, I., Holmberg, E. B., Nawka, T., Rosen, C. A., Schindler, A., Whurr, R., Woisard, V. (2008). Validation of the Voice Handicap Index by Assessing Equivalence of European Translations. *Folia Phoniatica et Logopaedica*, 60, 173-178.